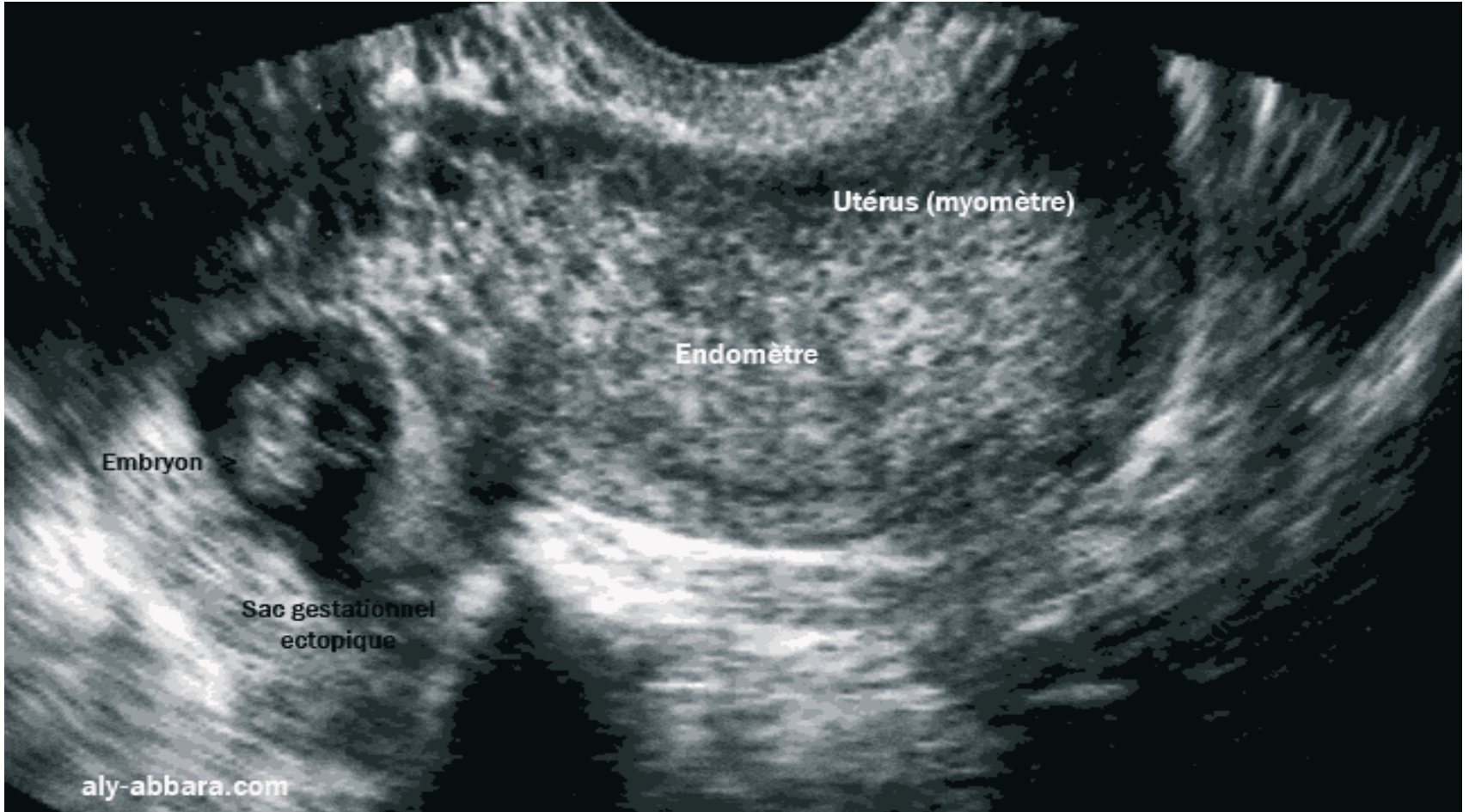


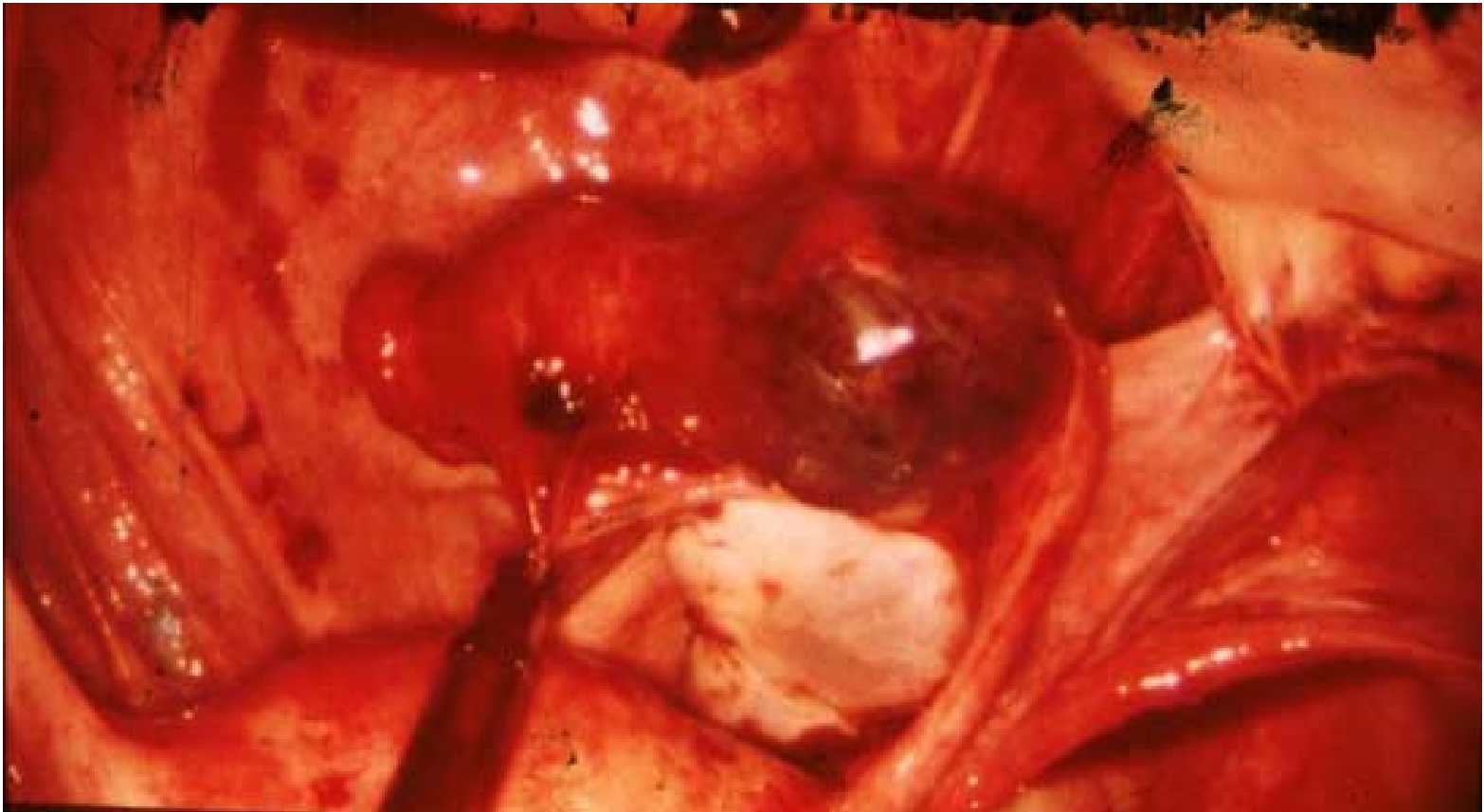
# Urgences chirurgicales de l'enfant

Dr Jacques Cesari  
Ajaccio juin 2010

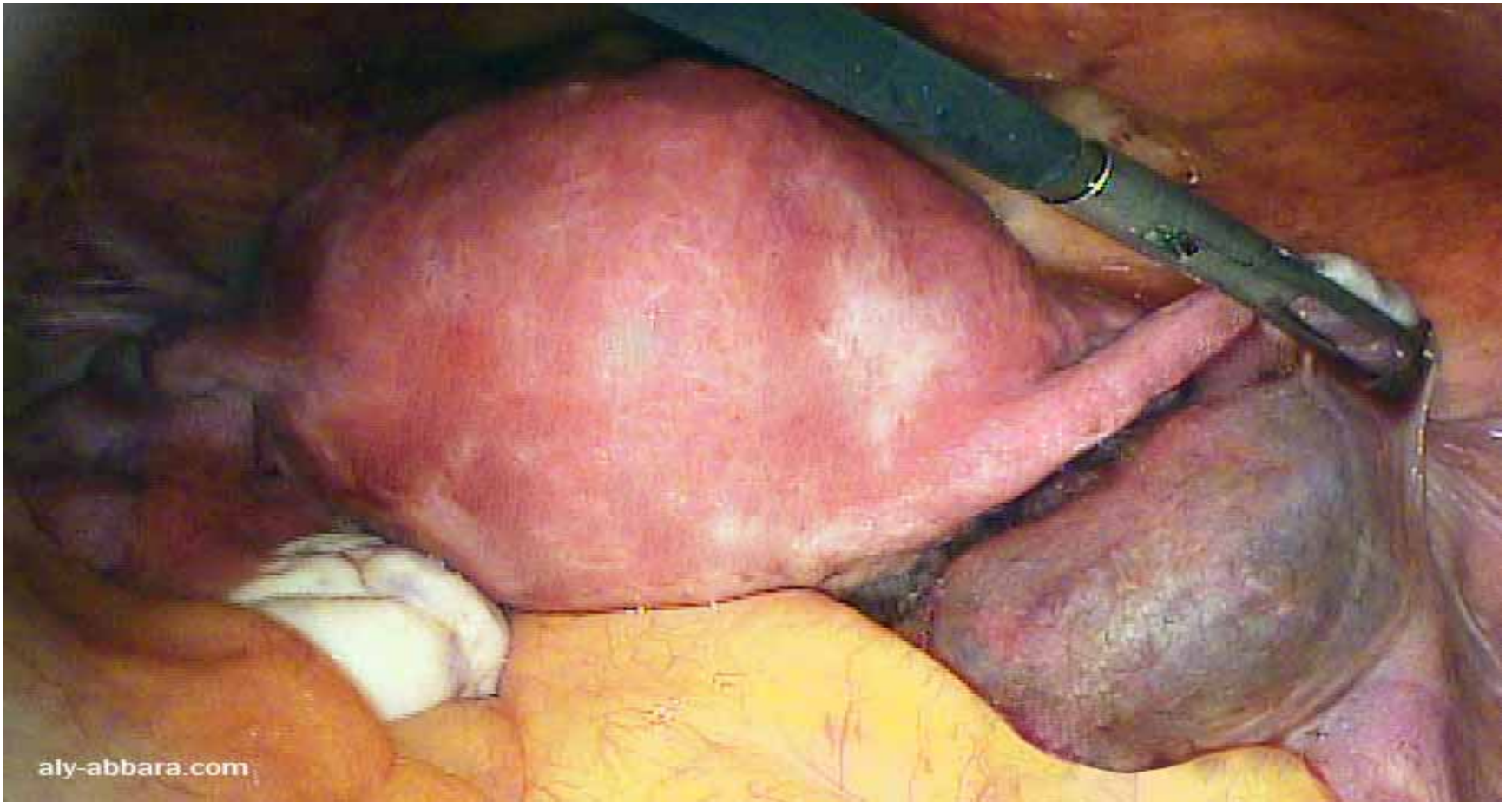# GEU(1)



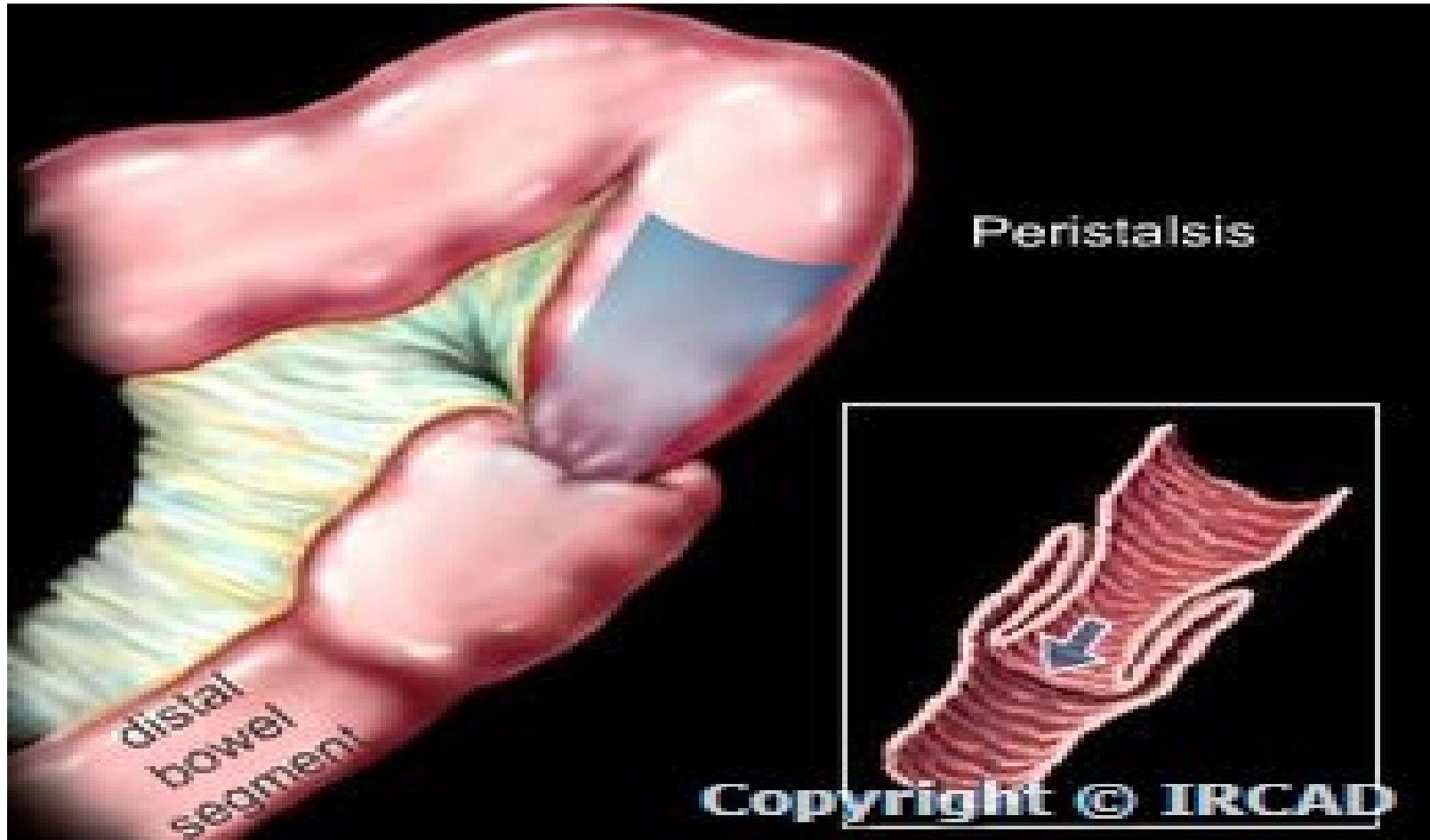
# LA GEU (2)



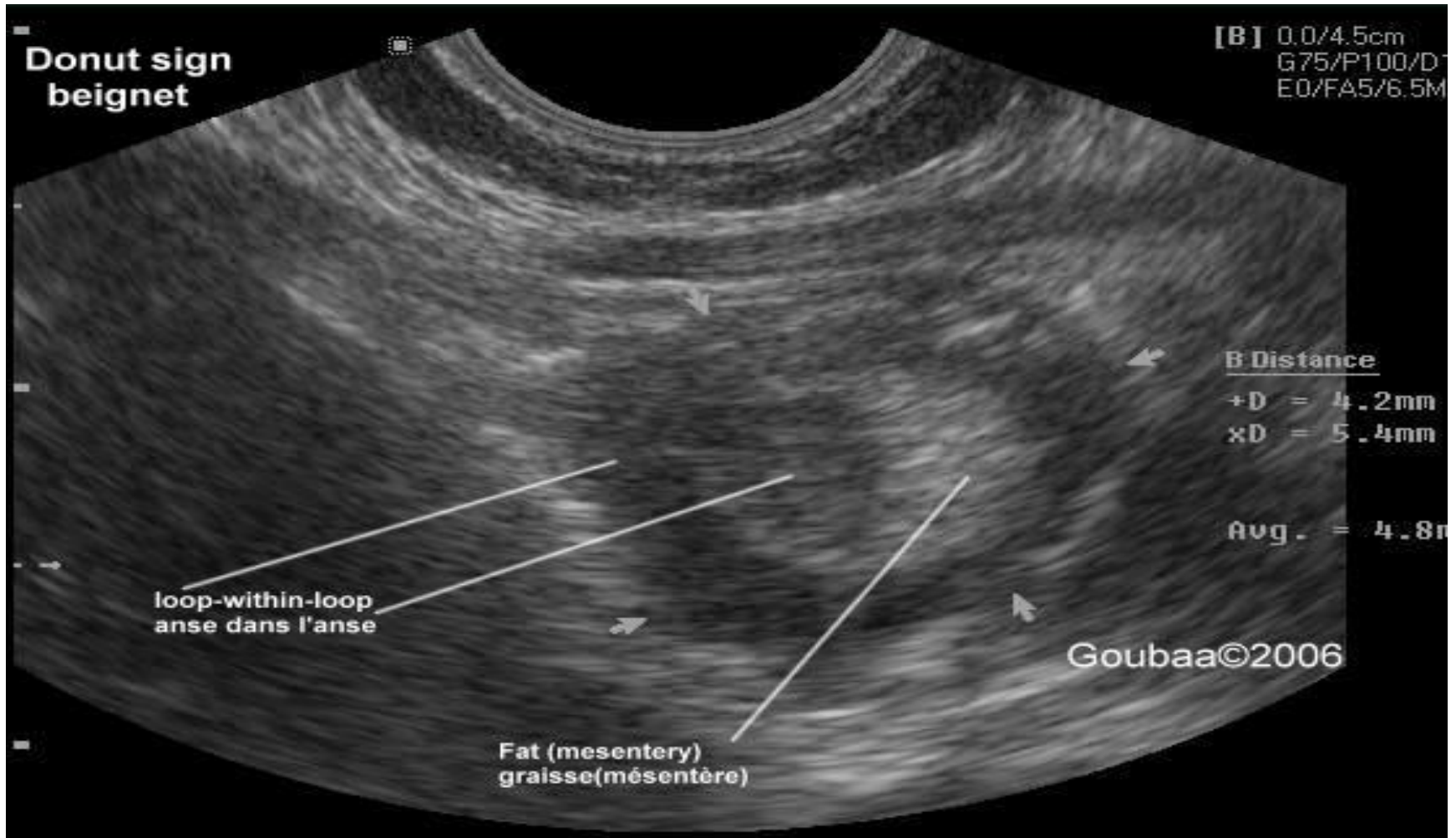
# GEU (3)



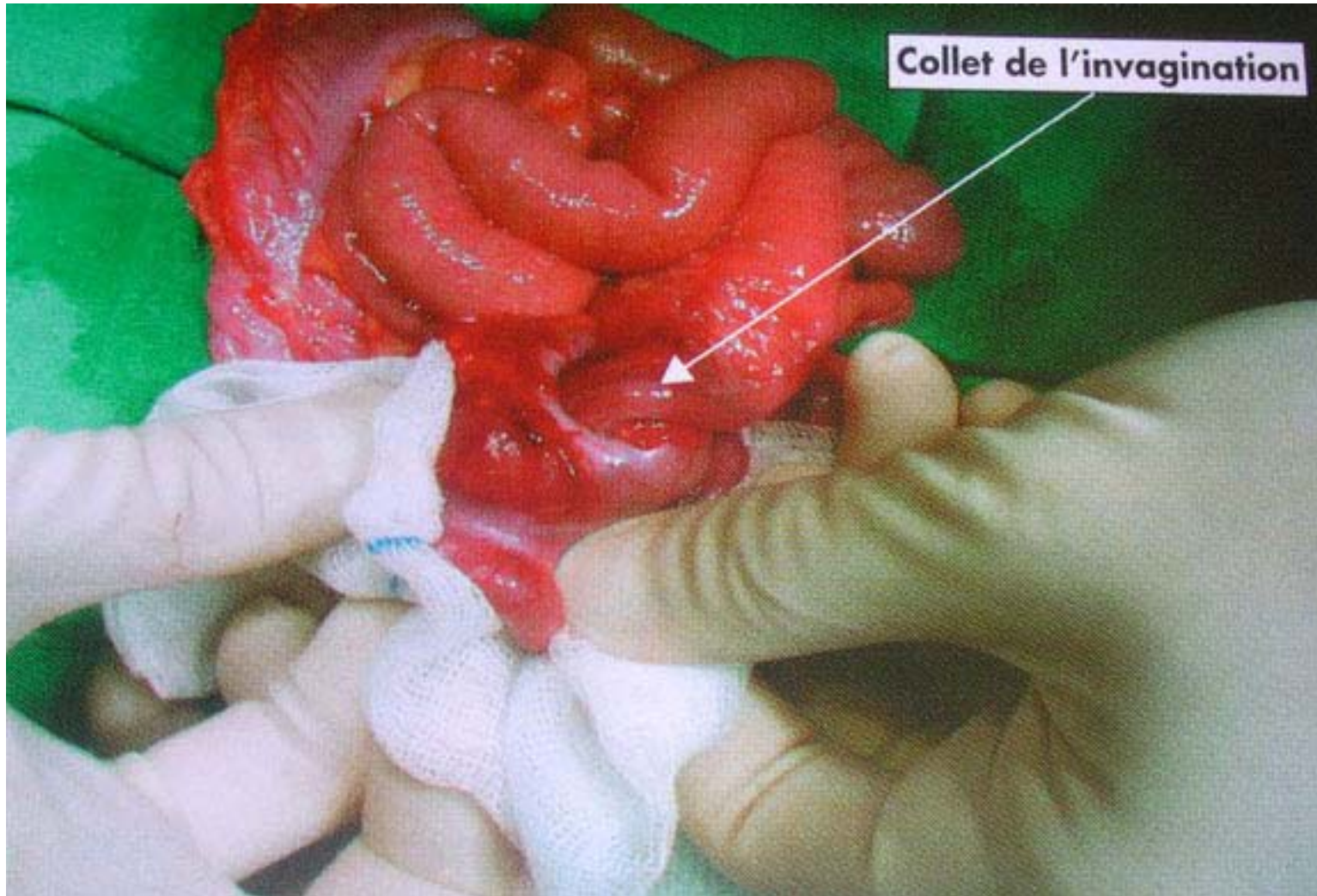# Invagination intestinale (1)



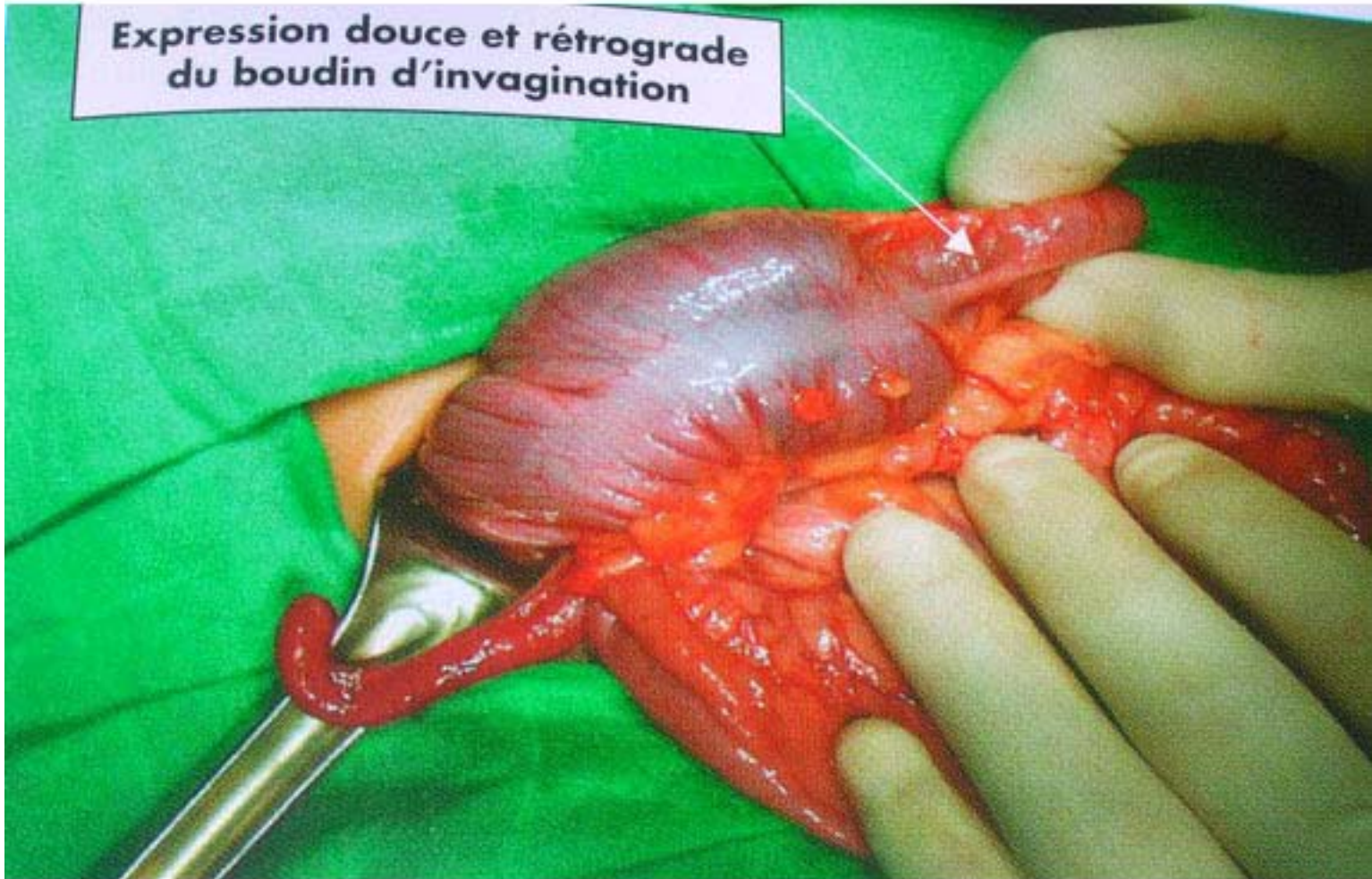# Invagination intestinale (2)



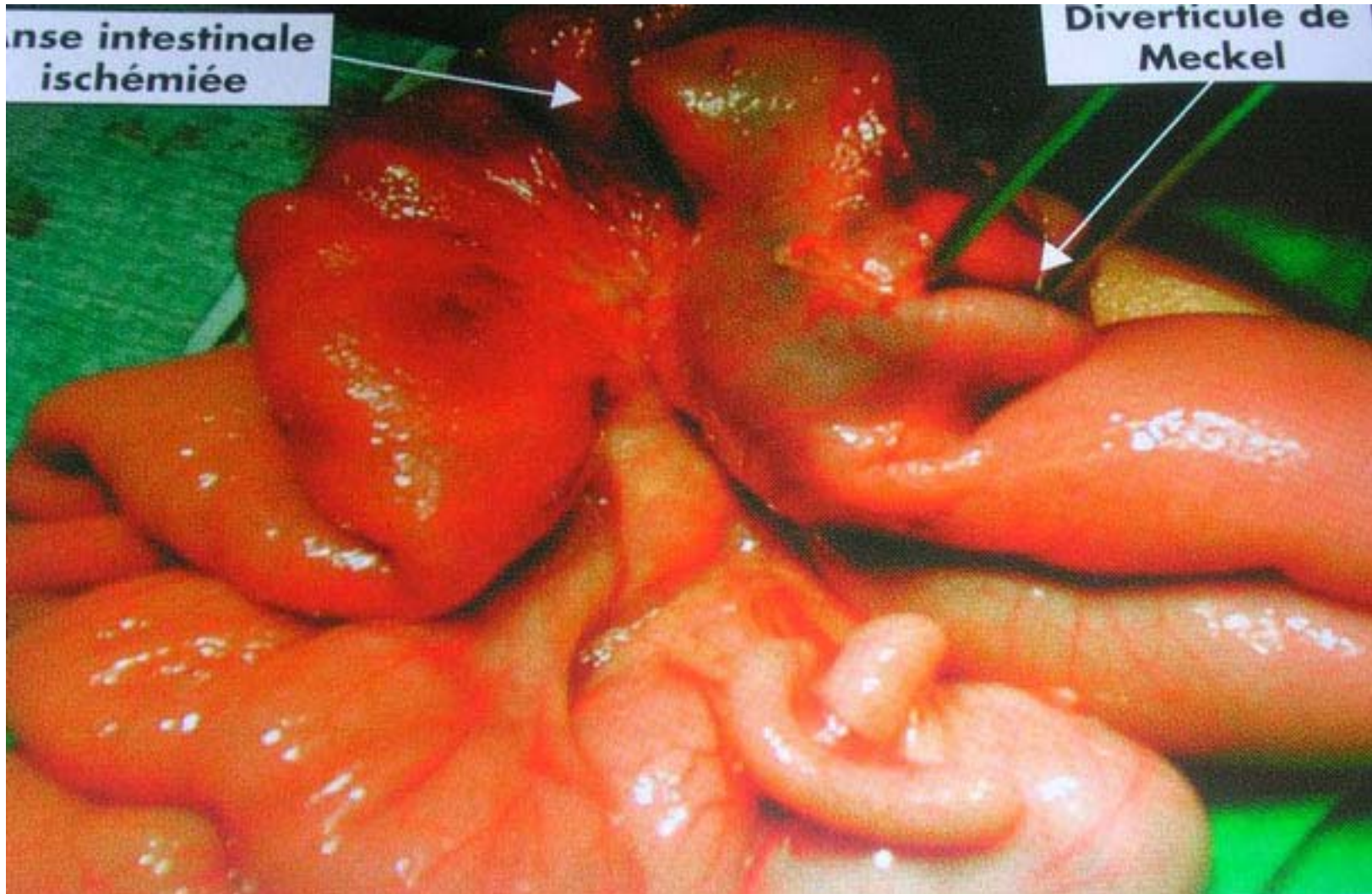
# Invagination intestinale (3)



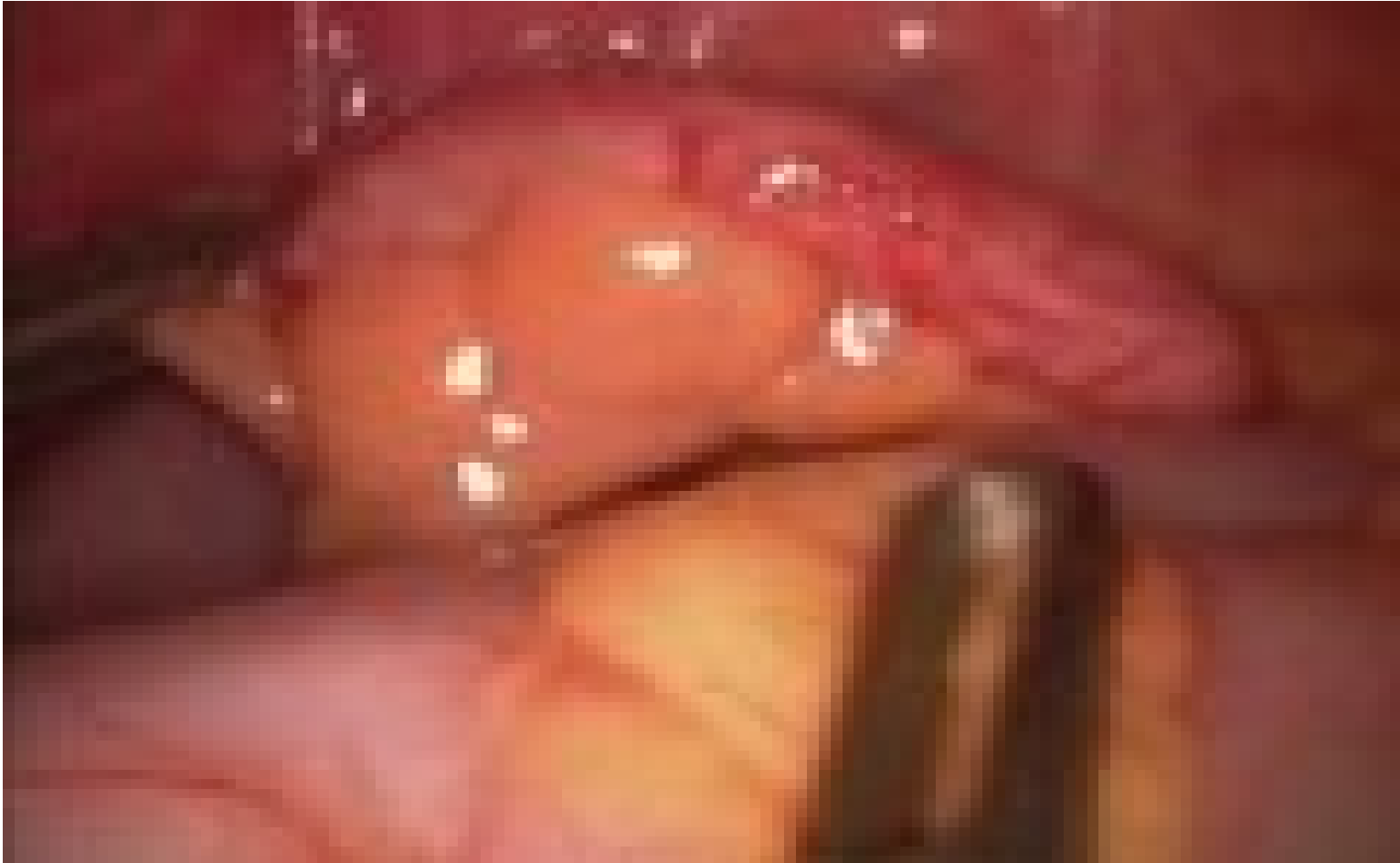# Invagination intestinale (4)



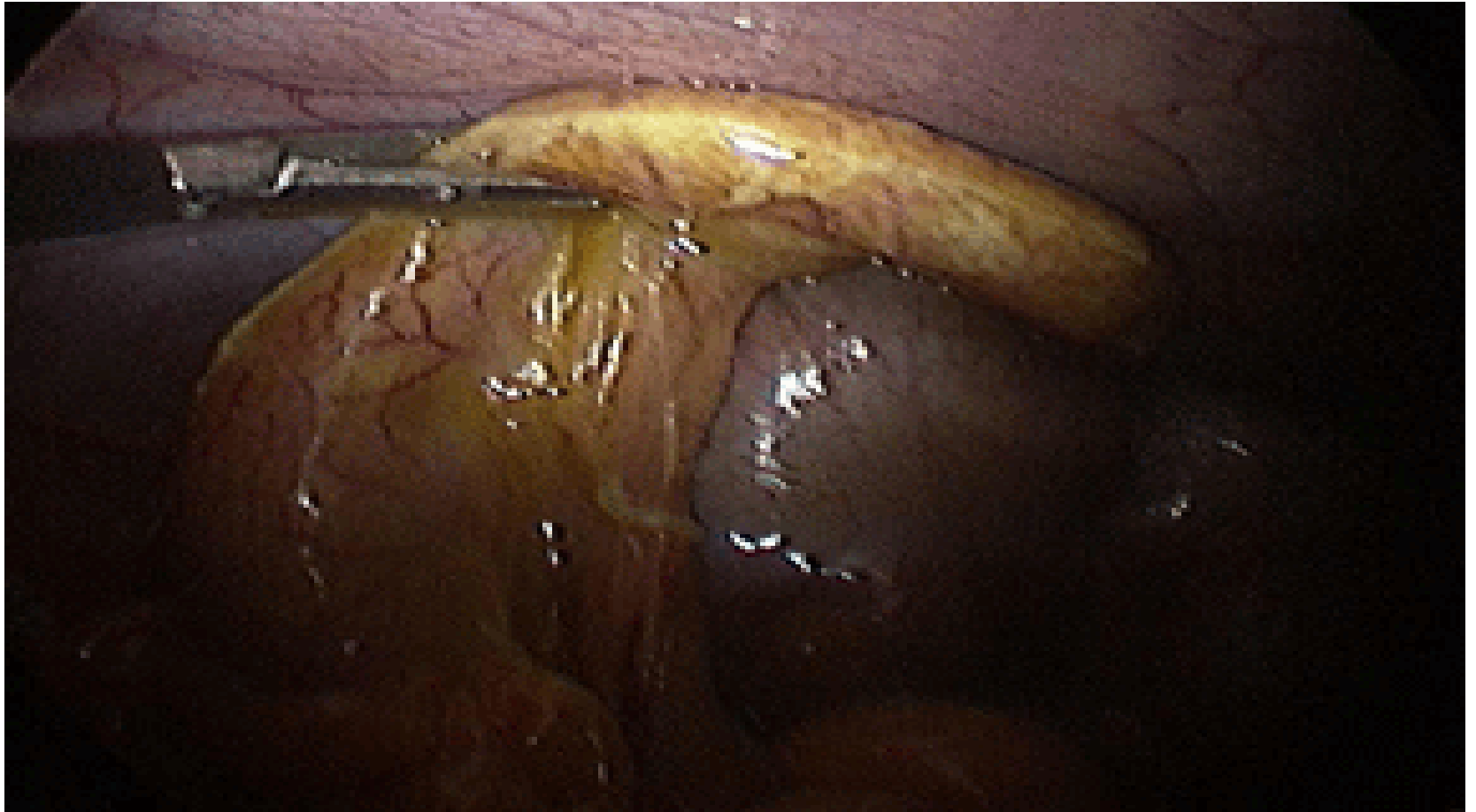# Invagination intestinale(5)



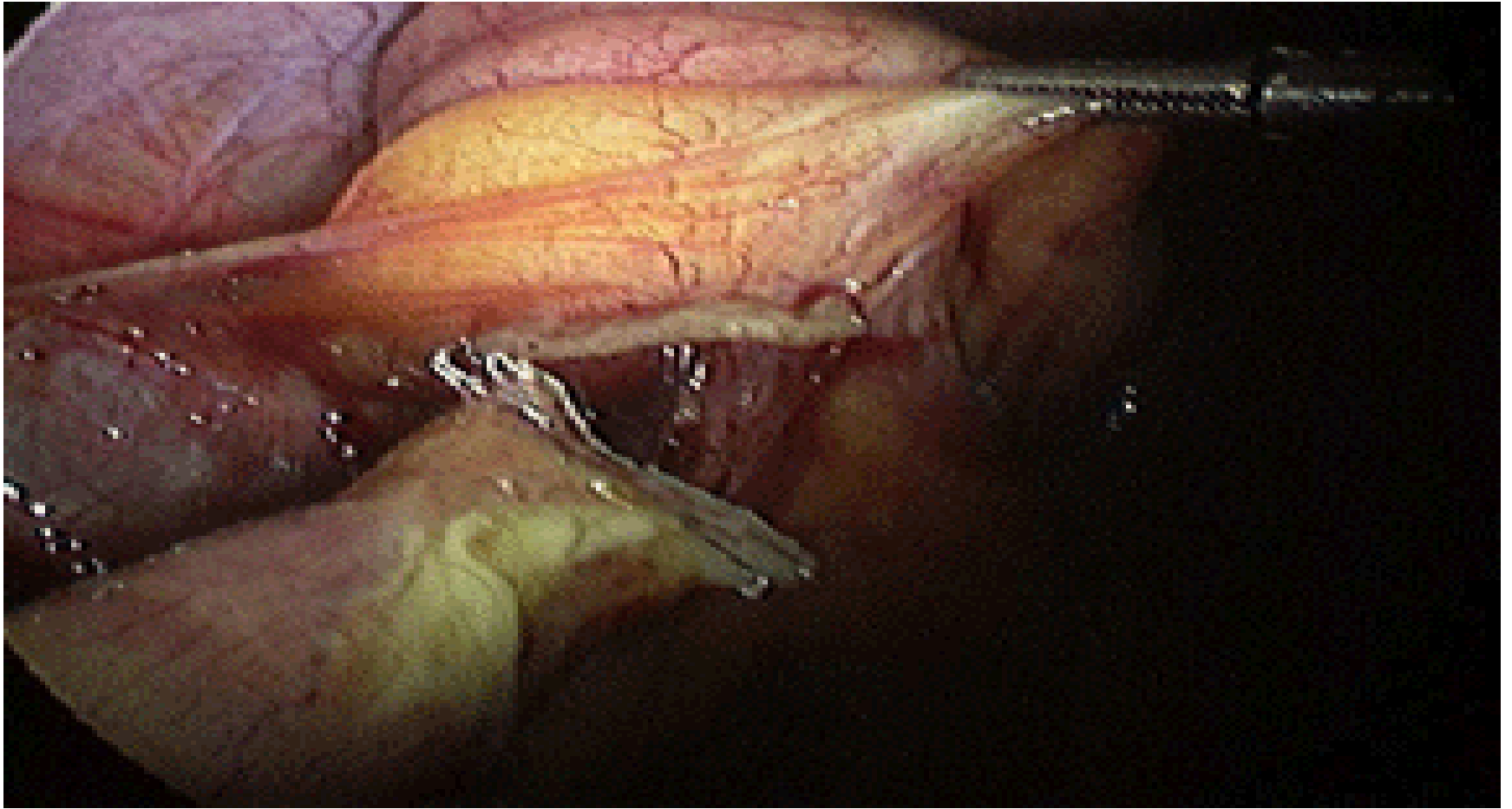
# Appendicite aigue (1)



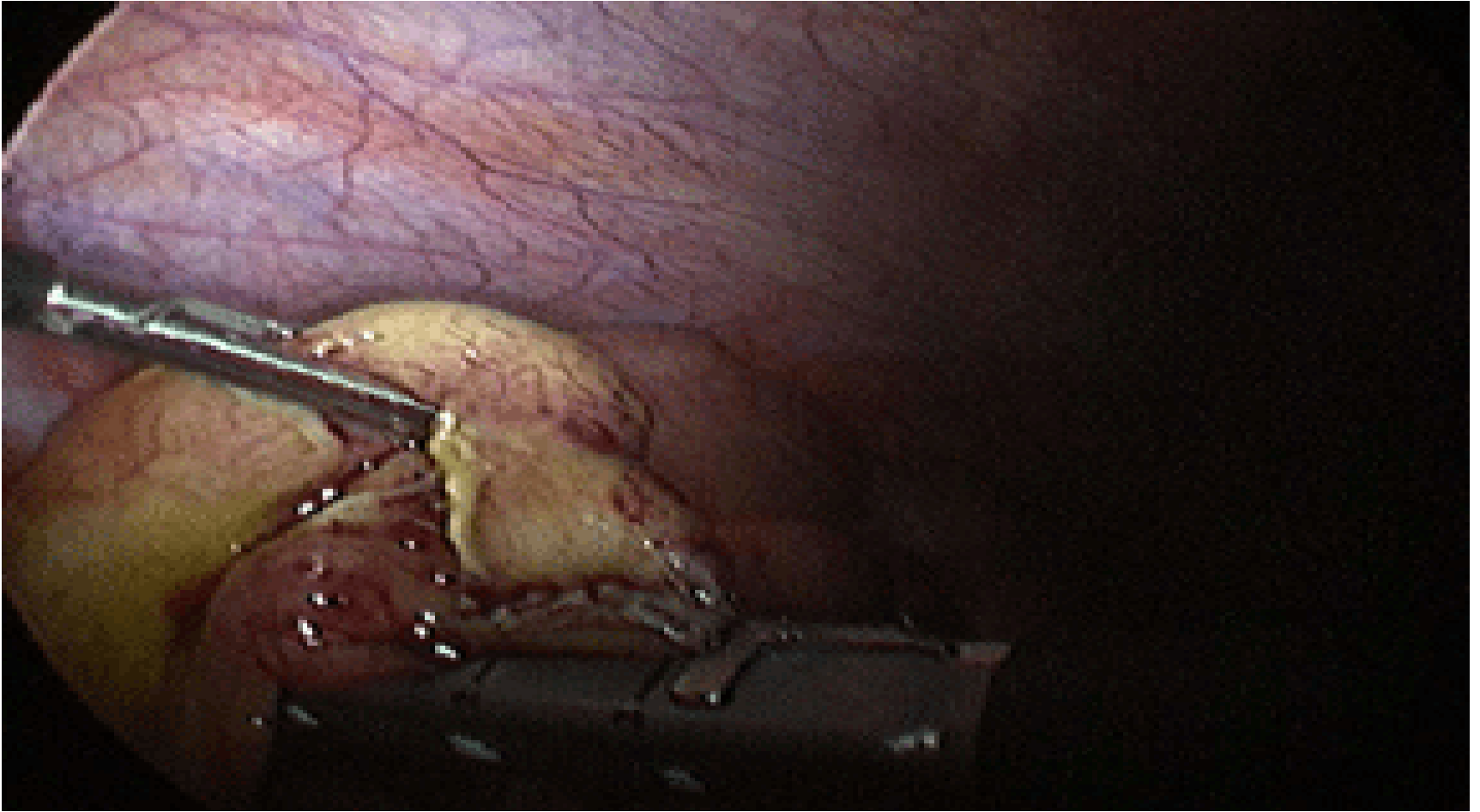
# Appendicite aigue (3)



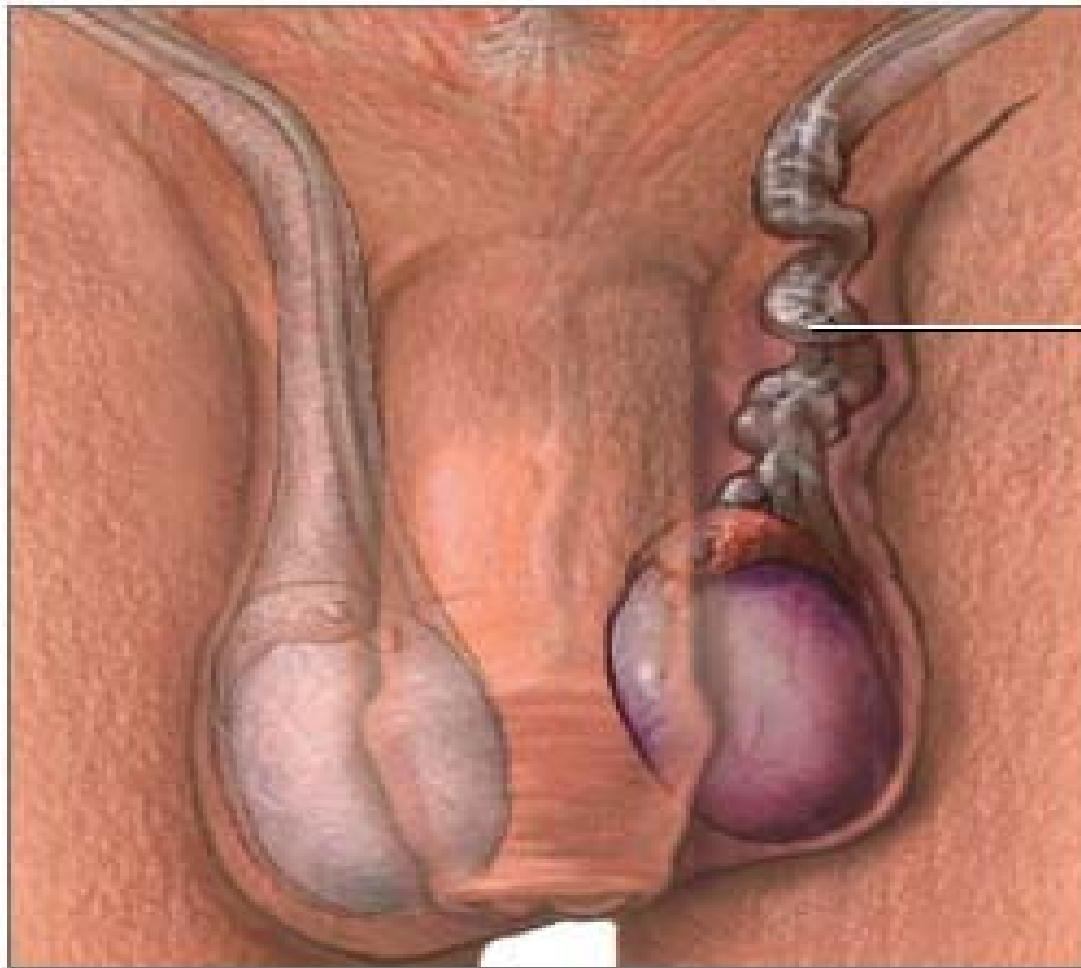
# Appendicite aigue (4)



# Appendicite Aigue (2)

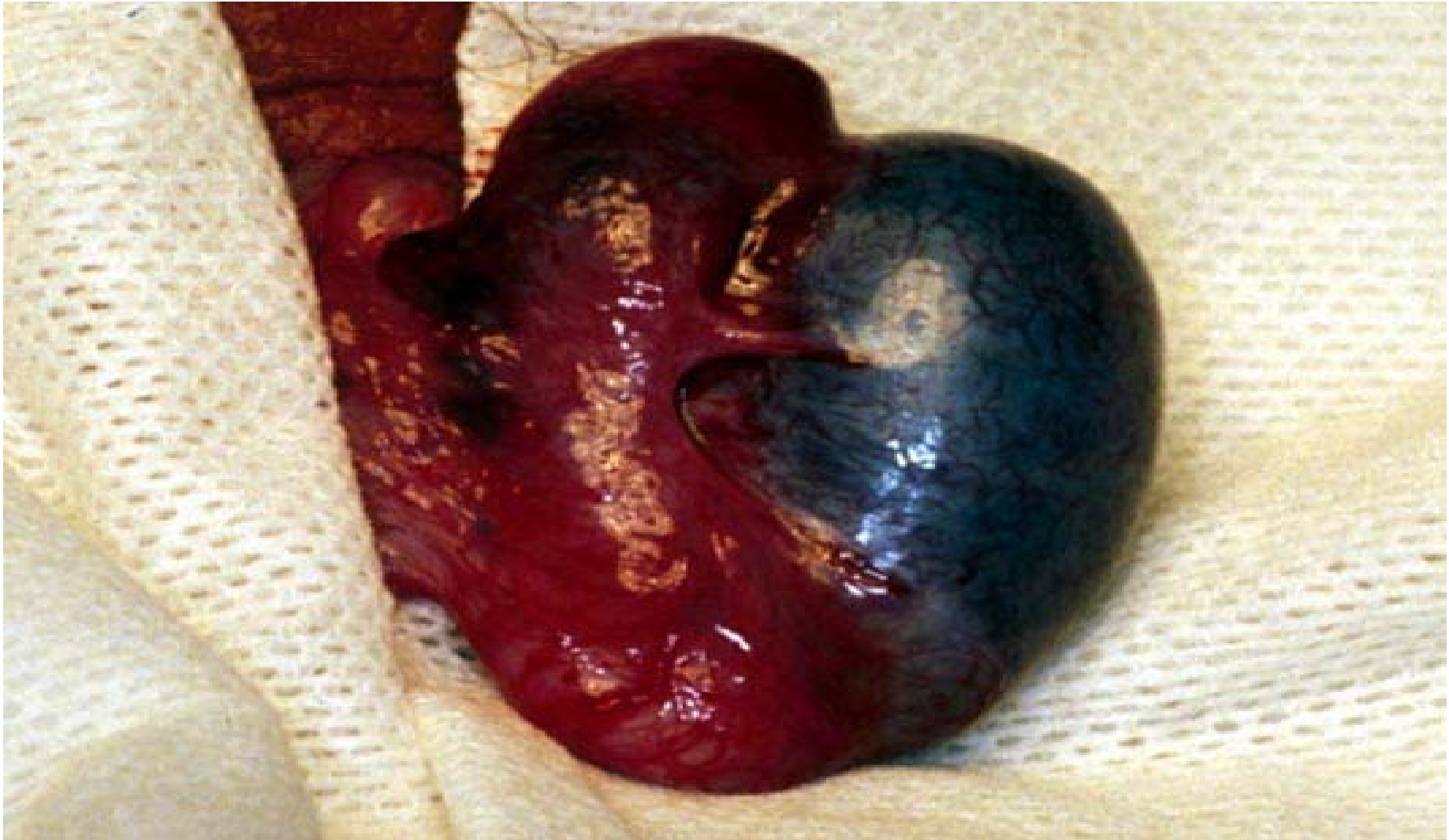


# Torsion testiculaire (1)



Twisted  
spermatic  
cord

# Torsion testiculaire (2)



# Torsion testiculaire (3)

